



DATE PRESENTING CLINICAL SIGNS

3.6.26

PATIENT

Dale Jr Richardson

SPECIES

Canine

BREED

Yorkshire Terrier

SEX

MN

AGE

5.4.12

WEIGHT

4.8lbs

INTERPRETED BY

Maggie Machen Lamy,
DVM, DACVIM
(Cardiology)

HOSPITAL NAME

Animal Clinic of
Whiteford

REFERRING VET

Dr. Everhart

INVOICE

47134

History: Non-productive coughing and dyspnea.

-Current medications: Started Lasix.

-Sedation used: Not required to complete full diagnostic ultrasound.

-Pertinent previous ultrasound results: No previous.

-STAT: Approved.

-Imaging performed by: Stephanie Warga RDCS, RVT.

ECHOCARDIOGRAM FINDINGS

2D, m-mode, color flow and doppler imaging is available. Mild diffuse thickening of mitral valve leaflets with no prolapse into the left atrial lumen. No mitral regurgitation with no left atrial dilation. Normal LV diameter with adequate myocardial function. The tricuspid valve appears normal with trace tricuspid regurgitation. Increased velocity. Massive heterogenous mass seen suspected to be adjacent to the right heart with infiltration of the right atrium. (2.9 x 2.8cm in best-viewed cross section; however, this is an underestimation). The mass can be seen within the pericardial space as well adjacent the left heart and potentially within the left atrium. Compression is suspected. The pulmonic and aortic valves are normal in morphology and mobility. Normal pulmonic and aortic outflow velocities with laminar flow. No obvious aortic or pulmonic insufficiency. Small volume pericardial and pleural effusion noted.

CARDIAC CHART

CANINE CARDIAC PARAMETERS	MR VMAX (m/s)	TR VMAX (m/s)	LA/AO (Boon method)	LA/AO (Heart Base; Swe)	FS (%)	EF (%)	EPSS (cm)
NORMAL PARAMETER	4.5-5.5	<2.7	1.3	<1.6	28-40	40-100	<0.6
PATIENT	NA	3.1	NM	1.3	44	78	NM
CANINE CARDIAC PARAMETERS	HR (BPM)	AV VMAX (m/s)	PV MAX (m/s)	BODY WEIGHT (kg)	LA 2D short axis Base view (cm)	LVIDd Avg; 2D and m-mode short axis (cm)	LVIDs Avg; 2D and m-mode short axis (cm)
NORMAL PARAMETER	50-100	0.7-1.7	0.7-1.6	BELOW	BELOW	BELOW	BELOW
PATIENT	180	0.9	1.2	2.2	1.2	1.7	0.9
*Normal chamber parameters expressed as a mean value (SD)				3	1.27 (5.3)	2.46 (2.46)	1.36 (5.5)
BODY WEIGHT DEPENDENT PARAMETERS				5	1.40 (4.5)	2.74 (5.2)	1.60 (4.7)
<i>*Note: All measurements based upon multi-modal images and methods. An average value is reported.</i>				10	1.50 (3.8)	3.27 (3.5)	2.06 (3.1)
				15	1.83 (2.0)	3.71 (2.4)	2.43 (2.1)
				20	2.02 (1.9)	4.14 (2.2)	2.80 (2.0)
				25	2.18 (2.4)	4.48 (2.9)	3.10 (2.5)
				30	2.33 (3.3)	4.83 (3.9)	3.39 (3.4)
				35	2.48 (4.3)	5.17 (5.0)	3.69 (4.5)
				40	2.62 (5.2)	5.48 (6.1)	3.96 (5.4)
				50	2.88 (7.1)	6.07 (8.3)	4.46 (7.4)

INTERPRETATION OF THE FINDINGS & FURTHER RECOMMENDATIONS

Cardiac neoplasia is identified with infiltration of the cardiac chambers. The exact origin is difficult to determine; however, the right heart is suspected. That being said, the heart base is also a possibility.

Regardless of origin or tumor type, once a mass is infiltrating the cardiac chambers, the patient is at risk for congestive signs, malignant arrhythmias, and/or sudden death at any time. If it is unclear if pericardial effusion is due to compression/congestion or if a tumor bleed is also at play.

The most likely tumor type is of vascular origin such as a hemoangiosarcoma, although a chemodectoma cannot be ruled out. Regardless of tumor type, the issue is due to the mechanical obstruction and reflects a poor to grave prognosis. The best we can do is remove effusions if they occur and use medications for congestive heart failure/congestion to help slow development of fluid accumulation. The size of the mass should be relayed as a grave prognosis. Supportive care can be attempted; however, diuretics and cough suppressants are a band aid over a much bigger issue as the tumor continues to grow. Euthanasia would be a viable option in this case, given the severity of the issues.

Going forward there are some options for obtaining more information and potentially palliating this type of cancer. Should the client elect to proceed, a Radiologist review of 3-view films, thoracic CT scan and full systemic screening is advised. Radiation and/or chemotherapy can be discussed with an Oncologist. Additionally, full systemic evaluation should be considered to screen for ancillary lesions that may be able to be sampled.

High risk will always remain for recurrent effusions (pericardial, pleural or abdominal) and development of arrhythmias/sudden death at home. Monitor at home for progressive abdominal distention, labored breathing and/or lethargy and collapse. Significant activity restriction is advised.

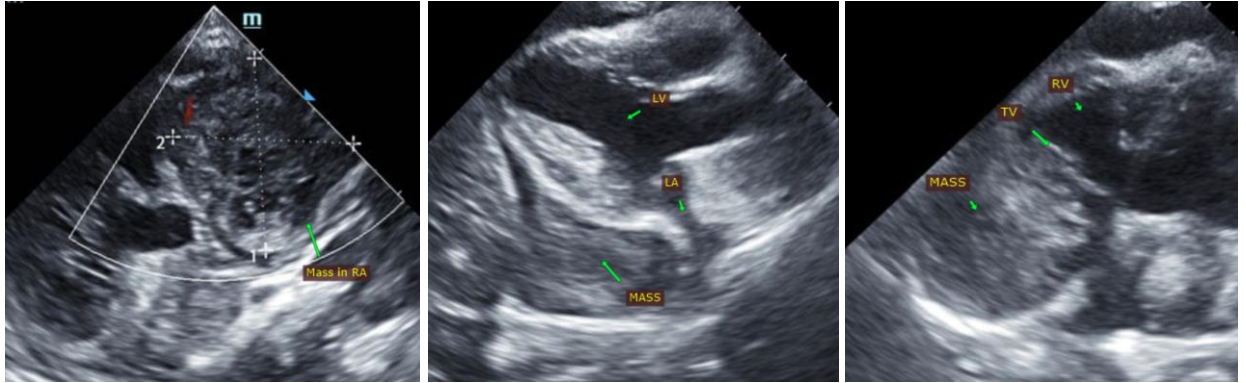
PLAN

Referral should be considered for advanced imaging if desired. If declined, consider euthanasia. If the client elects to attempt medical therapy, medications are as follows: Lasix 1mg/kg PO q12h. Administer Spironolactone 1-2mg/kg PO q12h. Administer Pimobendan 0.3mg/kg PO q12h. Administer Hydrocodone if needed. Abdominocentesis and/or thoracocentesis should be performed if needed in the future for patient comfort.

A renal panel and BP are recommended in 5-7 days, then every 2-3 months going forward. Consider referral for further diagnostics and/or Oncology consult. Euthanasia should be considered if quality of life suffers.

A recheck echocardiogram to reassess mass dimension and heart size is recommended in 2-3 months.

IMAGES



The information and recommendations provided are based on the images presented by the referring veterinarian. No evaluation can be communicated regarding pathology that was not visible in the image/video clips provided.

Thank you for this referral. This report was generated using transcription software, and minor dictation errors may be present. If the clinical or image interpretation does not parallel your findings or if I can be of any further assistance, please contact me.

Maggie Machen Lamy, DVM
Diplomate of the American College of Veterinary Internal Medicine (Cardiology)
info@sonopath.com